

New method to assess manual lymph drainage using lymphoscintigraphy

José Maria Pereira de Godoy¹, Adriana Joaquim Iozzi², Walter Ferreira Azevedo Jr³, Maria de Fátima Guerreiro Godoy⁴

¹Cardiology and Cardiovascular Surgery Department of the Medicine School in São José do Rio Preto (FAMERP) and CNPq (National Council for Research and Development), Brazil

²Nuclear medicine in Medicine School in São José do Rio Preto (FAMERP), Brazil

³Godoy Clinical Research-São Jose do Rio Preto, Brazil

⁴Medicine School in São José do Rio Preto (FAMERP), Brazil

[Received 27 I 2012; Accepted 10 II 2012]

Abstract

THE aim of this study was to describe a new variation of the technique to evaluate lymph drainage utilizing lymphoscintigraphy. A LS scan marks the route of lymphatic vessels and may be used to assess both manual lymph drainage and lymph drainage after using some apparatuses. This evaluation may be dynamic, collecting images whilst performing lymph drainage or static, with scans before and after the lymph drainage procedure.

KEY words: lymphoscintigraphy, manual lymph drainage, lymphedema

Nuclear Med Rev 2012; 15, 2: 75–77

Introduction

Manual lymph drainage was first described in 1936 by Emil and Estrid Vodder with a number of adherents helping to publicize their technique [1–3]. Over the last few decades, with the incorporation of the technique as an essential part of lymphedema treatment, physicians started to stimulate its use by physiotherapists and other professionals including occupational therapists and nurses. However, variations of this technique have appeared which need to be evaluated, as one of the criticisms related to lymph drainage techniques is the lack of studies that prove the efficiency of these variations.

Correspondence to: José Maria Pereira de Godoy MD, PhD
 Rua Floriano Peixoto, 2950
 São José do Rio Preto-SP, Brazil
 CEP: 15020-010
 e-mail: godoyjmp@riopreto.com.br

Lymphoscintigraphy among other indications is also used in the diagnosis and post-treatment evaluation of lymphedema [4, 5]. Its use has not been described immediately after performing lymph drainage in order to evaluate the effect of drainage. The aim of this study was to describe a new variation of the technique to evaluate lymph drainage utilizing lymphoscintigraphy.

A scan lymphoscintigraphy marks the route of lymphatic vessels and may be used to assess both manual lymph drainage and lymph drainage after using some apparatuses. When lymphedema is present, it is not always possible to mark the route of the lymphatic vessels in the affected limb, but this is usually possible in the unaffected limb. Thus, the unaffected limb may be used for the immediate evaluation of the lymph drainage of the affected limb. This evaluation may be dynamic, collecting images whilst performing lymph drainage or static, with scans before and after the lymph drainage procedure.

Case report

This new technique is illustrated here by describing the evaluation of a patient with grade 2 lymphedema of the left arm with a volumetric difference greater than 500 mL compared to the contralateral limb. The study was performed in the medical school in Hospital de Base in São José do Rio Preto, Brazil. The lymph drainage technique assessed was described by Godoy and Godoy (2004) [6]. The technique of lymph drainage employed uses manual compression movements, using a continuous pressure of 30–40 mm Hg, initiating in the region of the wrist and moving along the lymphatic course of the forearm and arm in the direction of the axillary region, a procedure that takes about two minutes. These values are recommended by lymph drainage techniques with practitioners being trained subjectively.

We performed lymphoscintigraphy after injecting 0.4 mL of dextran marked with technetium-99m intradermally between the 2nd and 3rd fingers of both hands. The patient was placed in the dorsal decubitus position with the arms elevated but placed above the head on the examination table.

The examination was dynamic over 40 minutes with images at 60 sec intervals (Figure 1) followed by a scan of the arms (Figure 2).

After this scan evaluation a second dynamic study as above followed during lymph drainage, to show the flow of the radioisotope to the axillary lymph nodes (Figure 3). Finally another scan of the arms was performed to analyze the quality of the images (Fig-

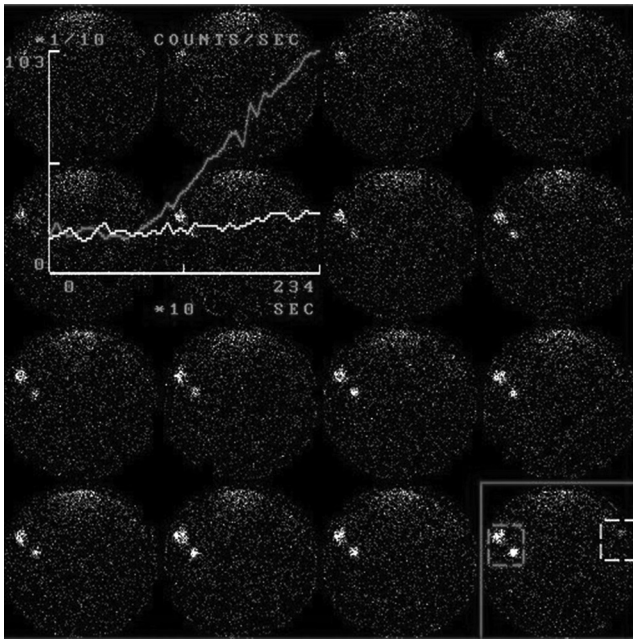


Figure 1. The initial dynamic study in the arms

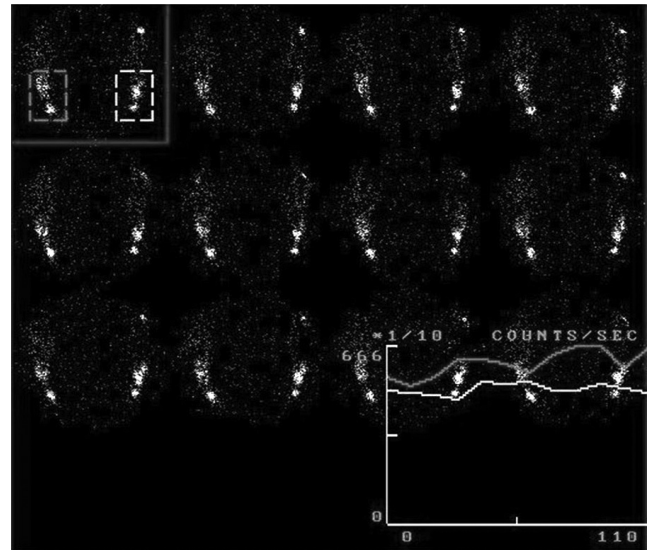


Figure 3. The dynamic study during 2 minutes of lymph drainage utilizing Godoy & Godoy technique a lymphedema arm

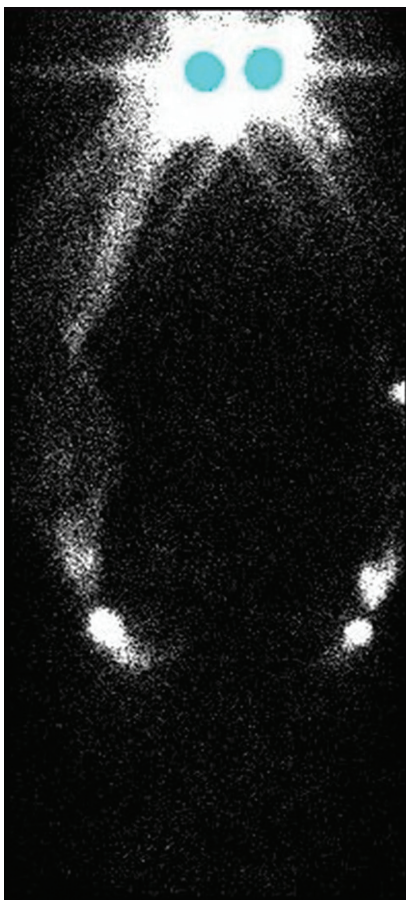


Figure 2. The scan after lymph drainage in arms

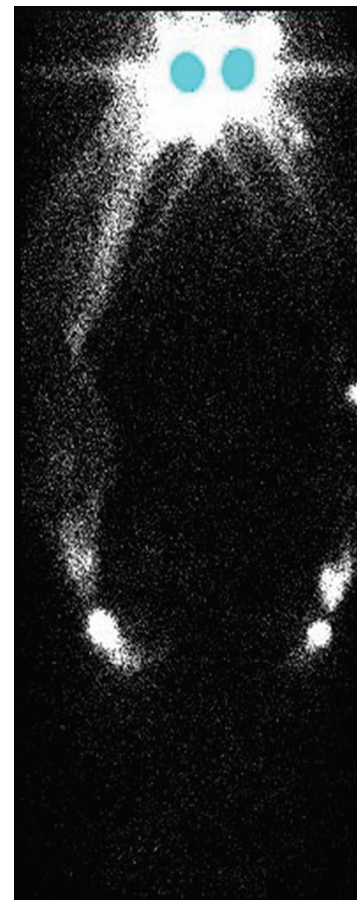


Figure 4. The scan after lymph drainage in arms

ure 4). The quantitative alterations were evaluated by the change in the number of particles that reached the axillar region after the start of lymph drainage. The images were analyzed by two nuclear physicians and one lymphologist.

The study was approved by the Local Ethics Research Committee and the patient signed a written consent form.

Figure 1 shows the baseline levels relative lymphedema in right arm (curve in yellow) and Figure 3 shows the variations after performing lymph drainage.

As is evident in Figures 2 (before) and 4 (after 2 minutes of lymph drainage), lymphedema in right arm demonstrate a reduction in the dermal reflux and the concentration of radioisotope in lymphatic collectors.

The current study describes a new technique to assess the efficacy of lymph drainage that has not been published in the ISI, Scopus and PubMed Electronic Databases. It is different from conventional evaluation methods because it assesses the efficiency during (dynamic) and immediately after drainage (static). Dynamic evaluation will measure variations of lymph obstruction at the lymph nodes or lymphatic vessels displacement.

The post-treatment scan shows the efficacy of lymph drainage and dermal reflux, by counting regions of interest over the affected and the non affected arm for comparison in order to identify lymph drainage obstruction. Evaluation using this technique requires standardization so that similar parameters are compared.

References

1. Kurz I. Textbook of Dr. Vodder's manual lymph drainage. Haug Verlag, Heideberg 1997: 139.
2. Leduc A, Leduc O. Rehabilitation protocol in upper limb lymphedema. *Ann Ital Chir* 2002; **73**: 479–484.
3. Godoy JMF, Godoy MFG, Batigalia F. Preliminary evaluation of a new, more simplified physiotherapy technique for lymphatic drainage. *Lymphology* 2002; **35**: 91–93.
4. Jensen MR, Simonsen L, Karlsmark T, Bülow J. Lymphoedema of the lower extremities — background, pathophysiology and diagnostic considerations. *Clin Physiol Funct Imaging* 2010; **30**: 389–398.
5. de Godoy JM, de Godoy MF, Valente A, Camacho EL, Paiva EV. Lymphoscintigraphic evaluation in patients after erysipelas. *Lymphology* 2000; **33**: 177–180.